

Case report

Electro-surgery as an aid to crown lengthening in the management of a mutilated tooth: A case report

Himanshu Dadlani*, H.S. Grover**, Suman Yadav**

ABSTRACT

The flourishing integration of periodontal and restorative dentistry for natural teeth requires sound knowledge and application of both mechanical and biological principles. While some restorative margins need to be placed at or below the margin of the free gingiva, this should be considered as a compromise and margins should not be placed more than 0.5 mm into a healthy gingival sulcus. Approximately 2 mm of healthy, sound supra-alveolar tooth surface is needed for attachment of the gingival tissues to the tooth. This dimension is called the biological width. In case adequate biological width does not exist, surgical or orthodontic procedures may be required to expose healthy tooth structure before final restorations are placed. This article explains the use of electrosurgery for the conservative crown lengthening of fractured tooth.

Key words: Eletrosurgery; Crown lengthening; Restorative destistry; gingival tissues.

INTRODUCTION

The importance of a sound periodontium for restoration of mutilated or traumatised teeth is often underestimated. It is necessary to prepare the periodontal tissues before restorative treatment to ensure good form, function, esthetics and patient comfort. To maintain healthy periodontal tissues, adequate width of attached gingiva and biologic width is a must. The biologic width is the distance established by the junctional epithelium and connective tissue attachment to the root surface of a tooth [1-2]. This distance on an average is 2.04 mm, of which 1.07 mm is occupied by the connective tissue attachment

and another approximate 0.97 mm being is occupied by the junctional epithelium. Impinging biologic width may cause loss of attachment and bone resorption [3-4]. Therefore, in crown lengthening, the position of the gingival margin is important.

In a crown lengthening procedure, the main aim is to establish a harmonious relation between the tooth supporting structures and to expose about 2 mm of sound tooth structure to allow for a "Ferrule effect" [5]. A ferrule, in respect to teeth, is a band that encircles the external dimension of residual tooth structure. It has been shown to significantly reduce the incidence of fracture in the endodontically treated tooth [6].

If there is less than 2 mm distance from the restoration's margin to the marginal bone, crown lengthening possibility should be considered in dental treatment plan [7-8]. The choice depends on relationship of crown-root-alveolar bone and final a esthetical expectations [9]. The crown lengthening procedure can be either planned surgically or combining methods of orthodontic eruption

Author's Affiliation: *Reader, **Prof. & Head, Department of Periodontics, SGT Dental College, Hospital & Research Institute, Gurgaon, Haryana. **Prof. & Head, Department of Conservative Dentistry & Endodontics, SGT Dental College, Hospital & Research Institute, Gurgaon, Haryana.

Reprints Requests: Dr. Himanshu Dadlani, Reader, Department of Periodontics, SGT Dental College, Hospital & Research Institute, Gurgaon, Haryana.

(Received on 15.04.2011 accepted on 26.08.2011)

and surgery. Surgical removal of soft tissue with a scalpel is a commonly used method but is associated with excessive blood flow and inadequate visibility. On the contrary, electrosurgery is a controlled, precise application of heat to the soft-tissue site achieved by means of carefully designed electrodes [10-12]. This procedure recontours the gingival tissue very accurately, the very reason it is also called as "Tissue Contouring System". This correction of tissue morphology reduces plaque and calculus retention and creates a physiologically healthy gingiva.

Electrosurgery - novel method for crown lengthening surgery

There are two basic types of electrosurgery units - monopolar and bipolar. In monopolar electrosurgery units, the current begins with the electrosurgery device and travels along a wire to the oral site and then to an indifferent plate placed behind the patient's back. As the surgical electrode contacts with the patient's oral soft tissues, heat is produced and controlled cutting is achieved. Crown lengthening with monopolar electrosurgery produces pain and smoke thus necessitating the use of local anesthetics. Bipolar electrosurgery devices have two electrodes on the cutting tip. The current flows from one electrode to the other, making a broader cut than does the monopolar unit, but eliminating the need for the indifferent plate. In this case report monopolar electrosurgery unit was used. (Table 1)

The margin of the provisional restoration should not hinder healing before the biologic width is established by surgical procedures. Therefore, a restorative treatment should be initiated after 6 weeks.

Case Report

An 18 year old male patient reported with the chief complaint of fractured maxillary right lateral incisor due to trauma. Clinical examination showed transverse fracture of crown portion of the tooth [Fig1]. Clinically, the fracture line was supra gingival on the

labial aspect and sub gingival on palatal aspect. On probing 4mm pseudo pocket was present on palatal aspect. Intraoral periapical radiograph showed complete formation of the apex of the lateral incisor. No fracture line was observed in other incisors. The remaining coronal portion of the fractured tooth on labial aspect was only 1mm and was found to be insufficient for the retention of prosthesis. Endodontic therapy was carried out immediately [Fig2].

Fig. 1. IOPA radiograph of fractured right maxillary lateral incisor

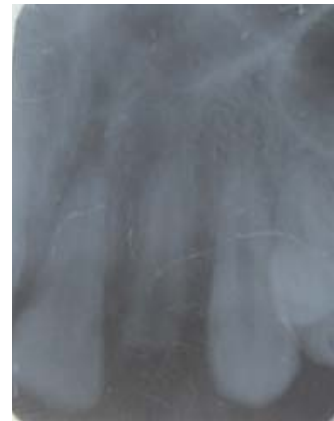

Fig. 2. Clinical view of fractured right maxillary lateral incisor

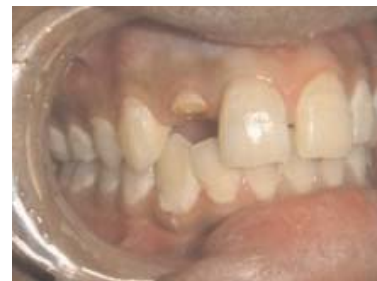
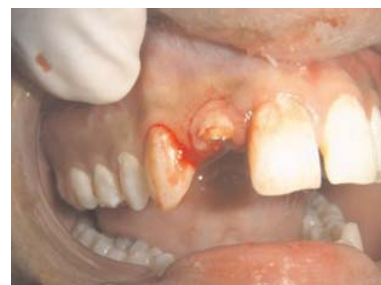
Fig. 3: A primary incision made against the alveolar crest using #15 blade along the gingival surface



Considering the age of the patient, following treatment options were discussed with the patient

1)Extraction of fractured tooth, followed by replacement with interim removable prosthesis. Final prosthesis would be either Implant or Bridge.

2)Conservative management through endodontic therapy, crown lengthening procedure and restoration using fibre post, composite buildup and ceramic prosthesis.

The second option was chosen as the line of treatment.

PROCEDURE

Local anesthesia was given by infiltration in labial sulcus and palate. A primary incision was made against the alveolar crest using #15 blade along the gingival surface[Fig3].

A #12 blade was used to make the second incision through the gingival sulcus to the alveolar crest. A third incision was made with an Orban interdental knife following the morphology of alveolar crest and the collar of tissue was removed as one circular mass[Fig 4].

This was followed by removal of excessive soft tissue on labial and palatal aspect using electro-surgery unit (Bonart Art Electro-surgery Unit) [Fig5,6]. be Current used in electro-surgery unit was fully rectified filtered (0.9 amperes, 230 volts, at 1.5-1.7MHz working frequency) as the electrode tip cuts but does not drag. After removal of excessive soft tissue, a flap was reflected and slight rounding of interdental bone was done on mesial and distal aspects with round bur without disturbing the supporting bone. Osteoplasty done was sufficient for exposing 3 mm of the sound tooth structure coronal from the alveolar crest along the tooth circumference. This was followed by suturing the operated area and placing coe-pak (GC company,USA) [Fig7, 8]. Patient was recalled after a week where coe-pak and sutures were removed. Electro-surgery unit along with tips is shown in [Fig6].

Fig. 4. A #12 blade is used to make secondary incision from the gingival sulcus to alveolar crest and the collar of tissue is removed as one circumferential mass

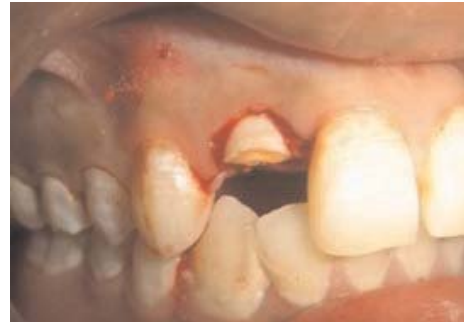

Fig. 5. Use of electro-surgery electrode for gingivectomy

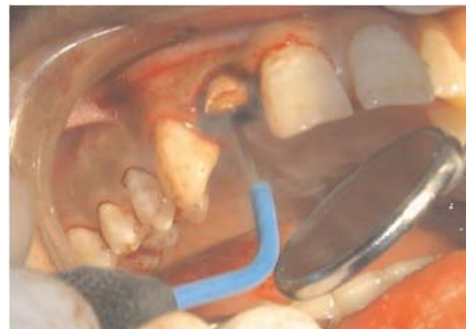


Fig. 6. Electrosurgery unit along with tips

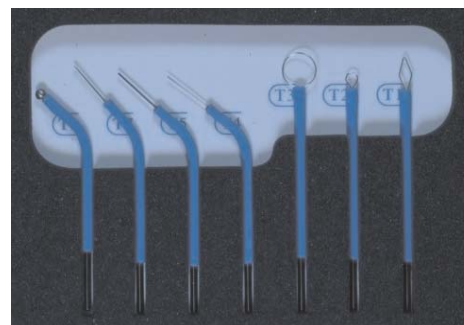
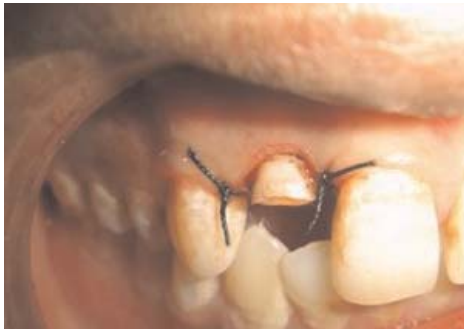
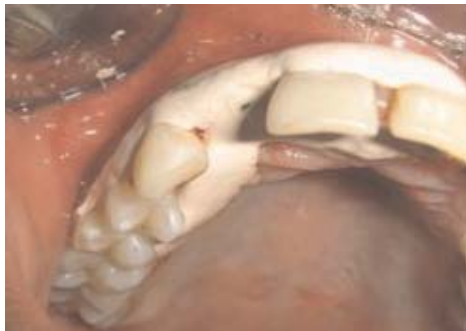
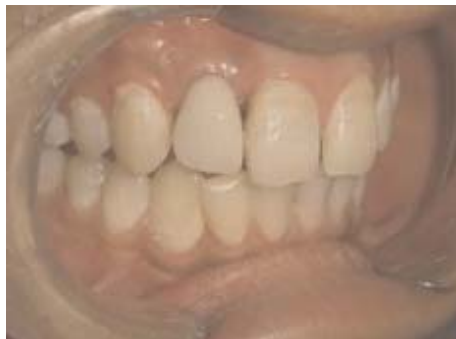Fig. 7. Suturing the operated area**Fig. 8. Coe-pak applied to the operated area****Fig. 9. Final restoration by PFM crown**

Fabrication of fiber post and porcelain fused to metal crown

Later, the gutta percha was removed with Gates drills (Antaeos, VDW GmbH, Munchen, Germany) without enlarging the canal. At least 4 mm of gutta percha was left at the apex of the root. The depth of the prepared canal was measured using a periodontal probe, and the root canal drilled according to general principles until it measured the estimated depth required for the post. The inside of the

root was rinsed and dried carefully, and the working area was isolated from moisture by cotton plugs.

The root canal walls were etched with 37% phosphoric acid for 15 seconds, washed with spray, and then air dried. The excess water was removed from the post space using paper points. Subsequently, two consecutive coats of bonding agent (Single Bond 2, 3M ESPE, St Paul, MN, USA) were applied with a micro-brush and air dried, and then cured with LED light source of 1000 mW/cm² intensity (Elipar Free Light 2, 3M ESPE, St. Paul, MN, USA) for 20 seconds. To fit with the diameter of the canal, an EverStick Post (Stick Tech Ltd, Turku, Finland) with a diameter of 1.2 mm was used. The post was inserted into the root canal to the appropriate depth, and the coronal section of the post was then shortened to an appropriate length with sharp scissors.

Prior to cementation, a layer of light-curing resin adhesive was applied to the surface of the post by gently blowing the surface of the post with dry, oil-free air and curing with light for 10 seconds. After checking the fit of the glass fiber post inside the root canal, the post was also light cured for 20 seconds.

Dual-resin cement (Rely X Unicem, 3M ESPE, Seefeld, Germany) was used as a luting agent for the glass fiber post. The cement was applied with a lentulo spiral into the post space. The fiber post was immediately inserted into the post hole to the base of the prepared channel and light-cured from different positions for 2 minutes. Excess resin cement was removed with a clean micro-brush and the cement was light cured for 40 seconds. Core build up was done with dual core composite resin. Patient was recalled after 6 weeks and tooth restored with porcelain fused to metal crown(13). (Fig. 9)

CONCLUSION

Electrosurgery has several applications in almost all branches of dentistry, but this technique is not very widely used. Electrosurgery has always had serious

limitations in the oral cavity. Some problems include its inability to touch bone or metal, high heat and current spread, the need for a grounding pad, and the fact that it cuts by an advancing spark. These limitations have limited its acceptance by many general dentists and almost a complete avoidance by periodontists and oral surgeons. Regular users of Electrosurgery know from experience that when electrosurgery is applied according to principles, predictable and good wound healing can be achieved. electrosurgery can never completely replace the scalpel Even through and requires more knowledge and skill, the advantages outnumber and outweigh its disadvantages.

REFERENCES

1. Takei HH; Azzi RR; Han TJ. Preparation of the Periodontium for Restorative Dentistry. In Newman, MG; Takei, HH; Carranza, FA; editors: *Carranza's Clinical Periodontology*, 9th Edition. Philadelphia; W.B. Saunders Company, 2002; 945.
2. Gargiulo AW, Wentz FM, Orban B. Dimensions and relations of the dentogingival junction in humans. *J Periodontol* 1961; 39: 261-267.
3. Padbury Jr. A, Eber R, Wang HL. Interactions between the gingiva and the margin of restorations. *J Clin Periodontol* 2003; 30: 379-85.
4. Nevis M, Skurow HM. The intracrevicular restorative margin, the biological width and maintenance of the gingival margin. *Int J Periodontics Restorative Dent* 1984; 4: 30-49.
5. Galen WW, Mueller KI. *Restoration of the Endodontically Treated Tooth*. In Cohen, S. Burns, RC, editors: *Pathways of the Pulp*, 8th Edition. St. Louis: Mosby, Inc, 2002; 784.
6. Barkhodar RA, Radke R, Abbasi J. Effect of metal collars on resistance of endodontically treated teeth to root fracture. *J Prosthet Dent* 1989; 61: 676.
7. Cunliffe J, Grey N. Crown Lengthening Surgery – Indications and techniques. *Dent Update* 2008; 35: 29-35.
8. Levine DF, Handelsman M, Ravon NA. Crown lengthening surgery: a restorative-driven periodontal procedure. *J Calif Dent Assoc* 1999; 27: 143-51.
9. Bateman GJ, Karir N, Saha S. Principles of crown lengthening surgery. *Dent Update* 2009; 36(3): 181-5.
10. Louca C, Davies B. Electrosurgery in restorative dentistry: 2. clinical applications. *Dent Update* 1992; 19(9): 364–366.
11. Laser or electrosurgery? No consensus yet. *OR Manager* 1990; 6(12): 7-9.
12. Christensen J. Soft-Tissue Cutting with Laser Versus Electrosurgery. *J Am Dent Assoc* 2008; 139(7): 981-984.
13. Behle C. Light-transmitting glass fiber reinforced composite build-ups for endodontic treated teeth. *J Cos Dent* 1997; 13: 22-32.